



# Successful Panoramic Radiography



DENTAL PRODUCTS



## **SUCCESSFUL PANORAMIC RADIOGRAPHY**

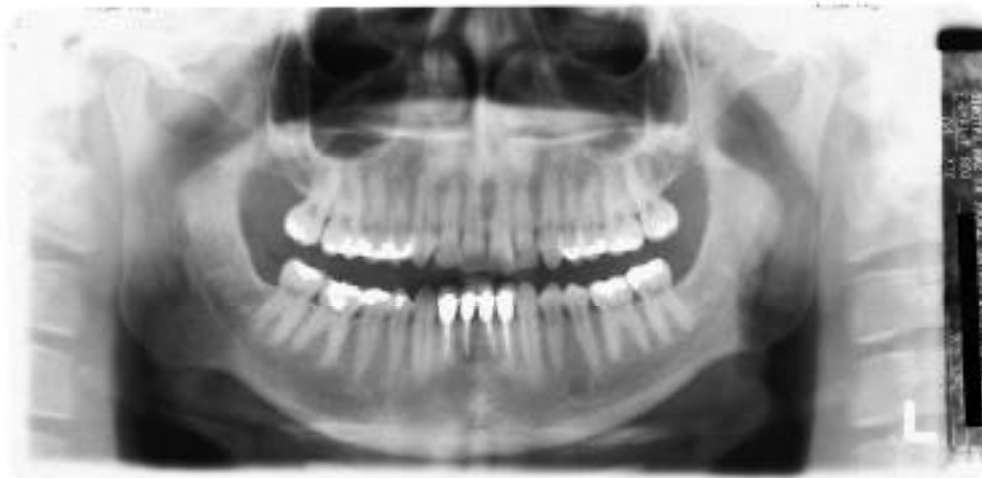Edited by Birgit Junfin Glass, D.D.S., M.S.  
University of Texas Health Science Center Dental School  
San Antonio, TX 78284-7919

Illustrations were provided by the University of Texas Health Science Center  
at San Antonio, Dental School (UTHSCSADS)

# Contents

Introduction.....	page 3
Image Layer.....	page 4
Preparing the Patient for Positioning.....	page 5
Image Receptor.....	page 6
Exposure Settings.....	page 7
Self-Test.....	page 8
Common Errors in Processing.....	page 9-14
Common Errors in Instructing Patient.....	page 15-16
White (minus density) Artifacts.....	page 17-19
Black (plus density).....	page 20-21
Common Problems in Processing.....	page 22-24

## Panoramic Radiography



**Illustration No. 1:** A normal panoramic radiograph.

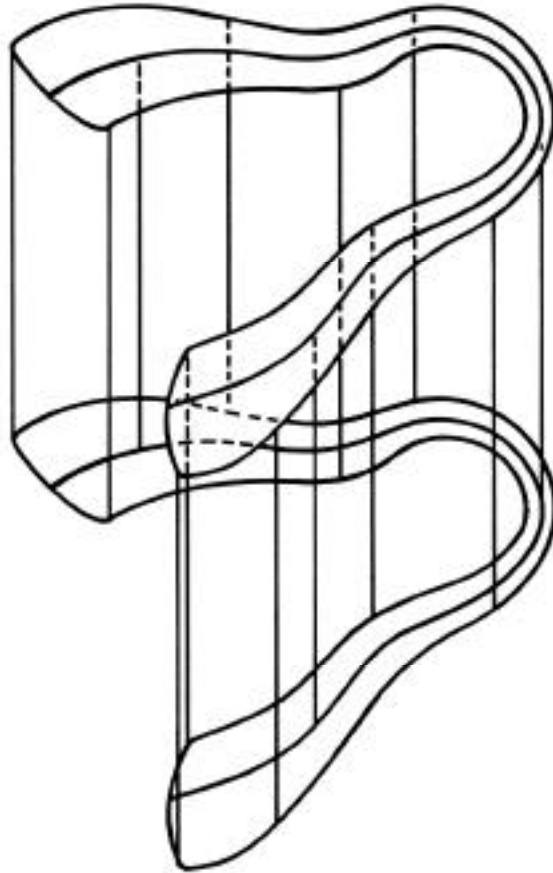
---

### Introduction

Panoramic radiography is a unique extraoral film technique that allows the dentist to view the entire dentition and related structures, from condyle to condyle, on one film. Obtaining a film such as the one shown in Illustration No.1 is possible only with attention to special details unique to this type of technique. The procedures and equipment for obtaining a panoramic radiograph have steadily improved since the first one taken in 1934. A panoramic radiograph can be made with the patient sitting, standing or lying down. In all situations, the manufacturer's instructions must be carefully followed and the patient must remain perfectly still while the x-ray beam and image receptor (film-screen combination) rotate together around the patient's head.

This booklet will address problems commonly associated with panoramic radiography and provide suggestions for possible solutions. Since it is not always obvious to the operator what error has been made, this booklet will approach the errors based on problems seen on the radiograph that decrease its diagnostic quality. Some of the problems and solutions referred to in this booklet may also apply to other techniques which use extraoral cassettes with film-screen combinations.

---



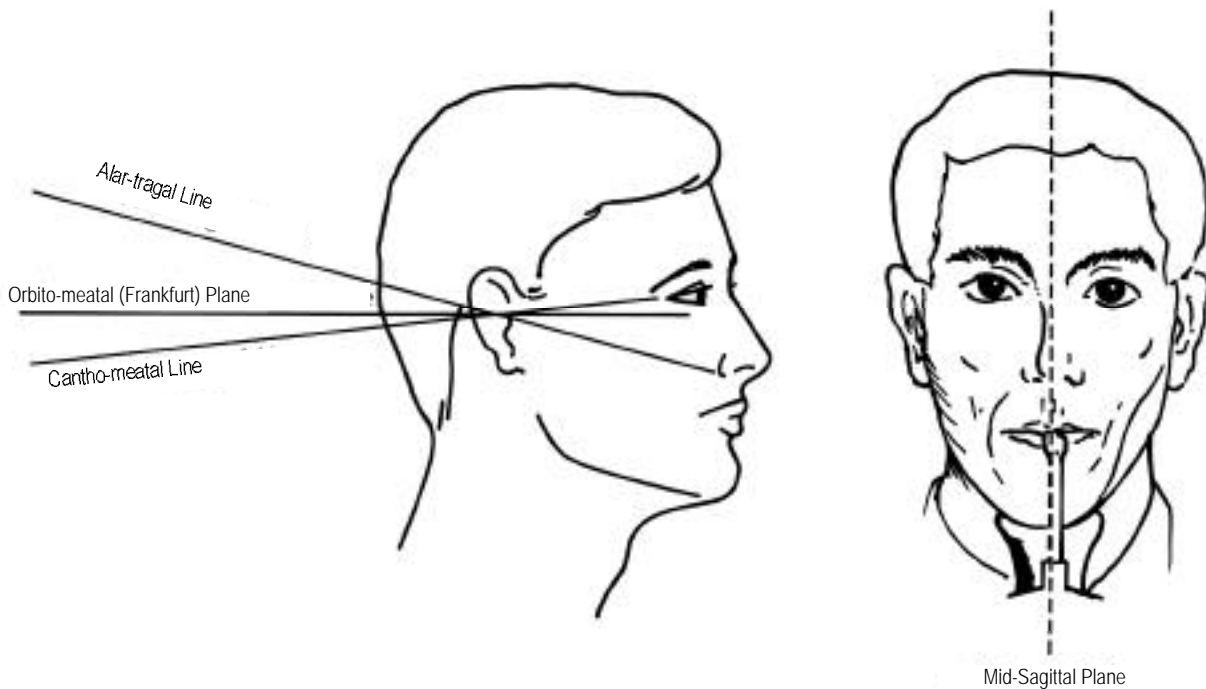
**Illustration No. 2:** An example of an "image layer" or focal trough."

---

### **Image Layer**

The image layer is an invisible area located in the space that lies between the source of the radiation and the image receptor. The shape of the image layer varies, depending on the equipment manufacturer. Illustration No. 2 identifies one example. The dentition and related structures must be positioned so that they fall within this image layer. The resultant image will have the least distortion and therefore will be most diagnostic. The image of structures which fall outside the image layer will be distorted. The further they are from the image layer, the greater their distortion. The distortion may be to the degree that the area is totally non-diagnostic. Panoramic units have one or more image layers designed to accommodate an "average jaw." Each panoramic unit comes with specific instructions on positioning the patient to ensure the dentition and related structures will fall into the image layer for that machine. The quality of the final film is related not only to the patient's position during the exposure, but also to how closely the individual's oro-facial region conforms to the image layer designed for an "average jaw."

---



**Illustration No. 3:** Four anatomical planes commonly used in positioning patients.

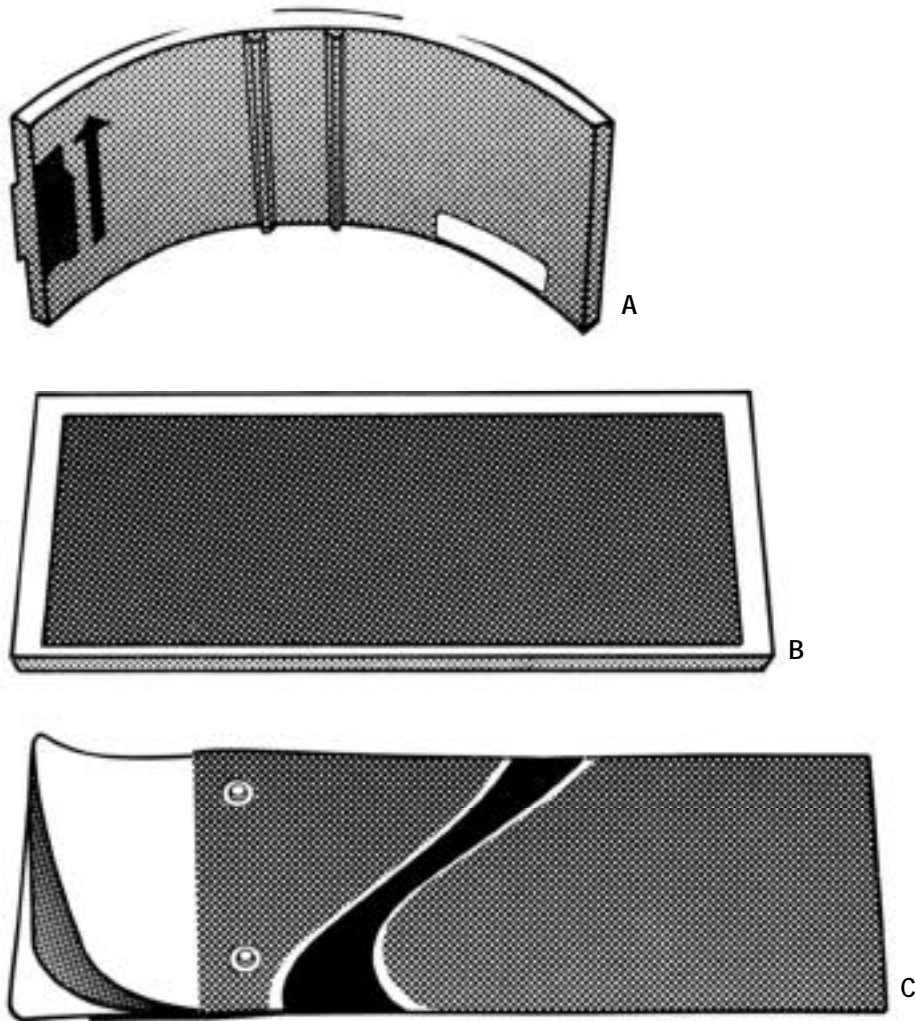
---

### Preparing the Patient for Positioning

The patient should be positioned according to the manufacturer's recommendations. Head positioning devices and chin rests are important for accurate placement. Take time to position the patient correctly and to explain the purpose and operation of the equipment.

Ask the patient to remove glasses, all jewelry or other metallic ornaments, or devices on and around the head and neck areas. Full or partial dentures should also be removed. Be sure to instruct the patient how to bite on the bite block, close his/her lips and place the tongue against the roof of the mouth. Panoramic-leaded aprons should be used. Unlike aprons for conventional radiography, these aprons cover the back and shoulders.

---



**Illustration No. 4:** Film cassettes. Figures "A" and "B" are rigid cassettes. In a rigid cassette, the intensifying screens are attached to the inside cover and base of the cassette. When the panoramic film is placed in the cassette, it lies in-between the screens. Figure "C" is a flexible cassette which has an opening at one end creating a pouch. The panoramic film is placed between two removable, flexible intensifying screens which are then slid into the pouch.

---

### Image Receptor

The image receptor in extraoral radiography is a combination of two intensifying screens with a film in between, all of which are enclosed in a protective light-tight container called a cassette. A cassette can be soft or rigid. Each intensifying screen contains a phosphor layer that fluoresces when activated by x-radiation which has penetrated the patient and cassette. This fluorescent glow is what exposes the film. This exposure method differs from conventional intraoral radiographs in which the x-rays directly expose the film. Film used in panoramic imaging is 10-60 times more sensitive to fluorescence than to x-rays; therefore, the amount of radiation needed to produce a high-quality film is less when using screens. As the x-ray beam and image receptor encircle the patient, the image is recorded on the film in vertical increments which are restricted by the narrow beam and collimation.

---

Factors to consider	Exposure setting
Obese patient	Use the next highest kVp or mA
Patient with large bone structure	Use the next highest kVp or mA setting
Patient with small bone structure	Use the next lower kVp or mA setting
Patient that is edentulous (toothless)	Use the next lower kVp or mA setting

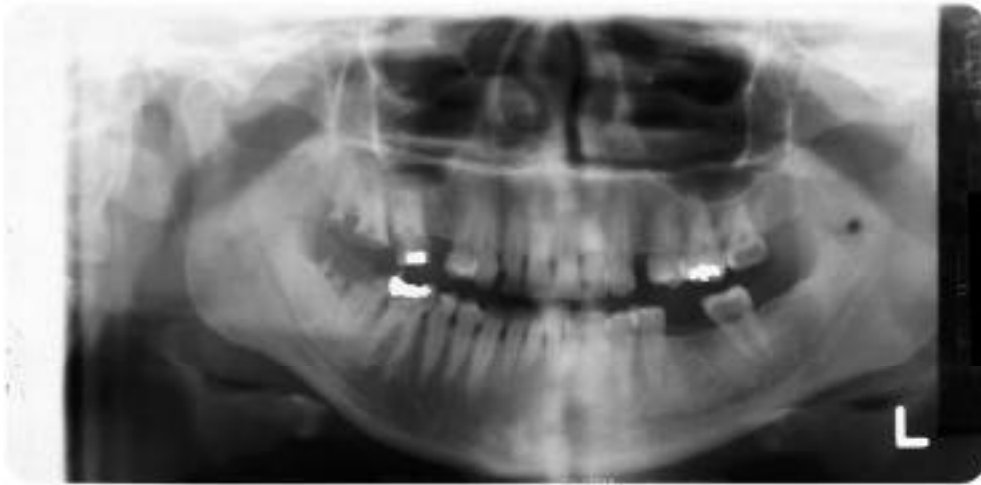**Illustration No. 5:** A list of common factors that affect exposure.

---

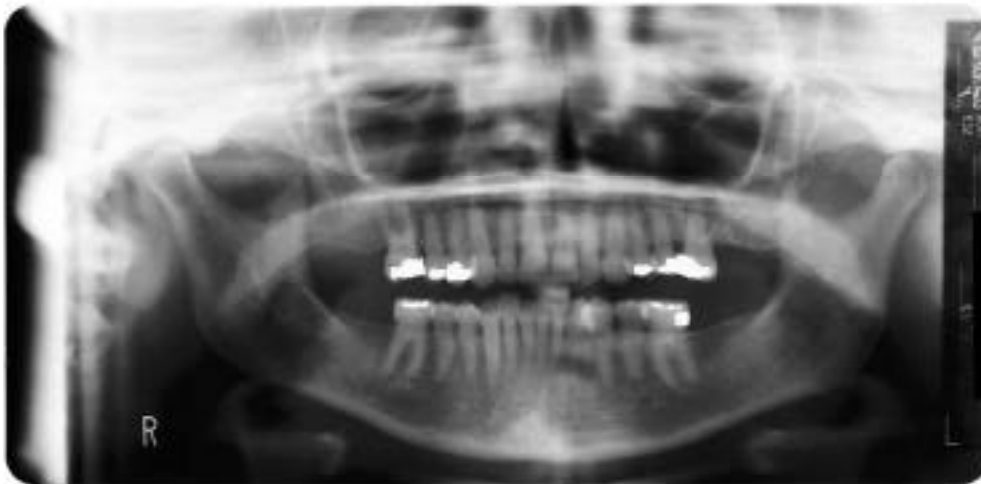
### Exposure Settings

The average kVp and/or mA setting is recommended by the unit's manufacturer, but can vary from patient-to-patient due to size, dentition, etc. In panoramic radiography, the exposure time is fixed by the time required to complete one full excursion of the assembly. There are other factors that can affect the average exposure setting recommended by the equipment manufacturer. A summary of some of these factors is listed in Illustration No. 5.

---



**Illustration No. 6:** Determine error(s).

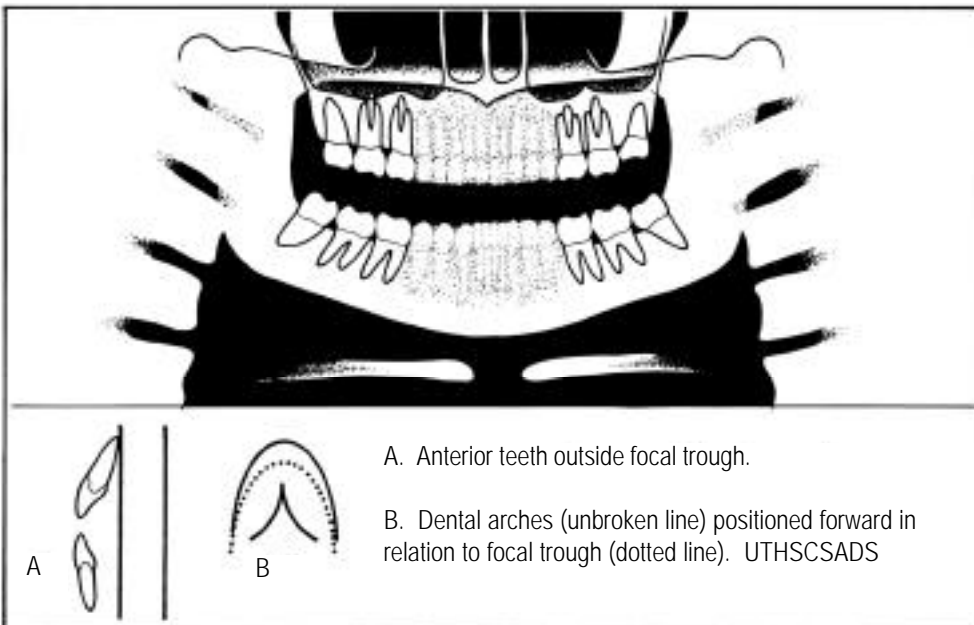
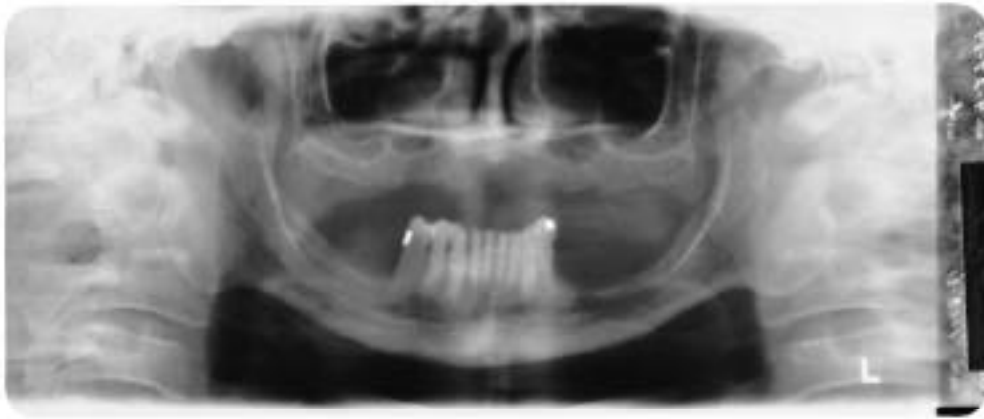

**Illustration No. 7:** Determine error(s).

---

### Self-Test

Before reading the sections that follow, Illustration Nos. 6 and 7 have a number of errors in them. See how many you can identify and consider what you would do to correct each error you identify. (Correct answers are located on the inside back cover of the booklet.)



**Illustration No. 8:** Patient is positioned too far forward.

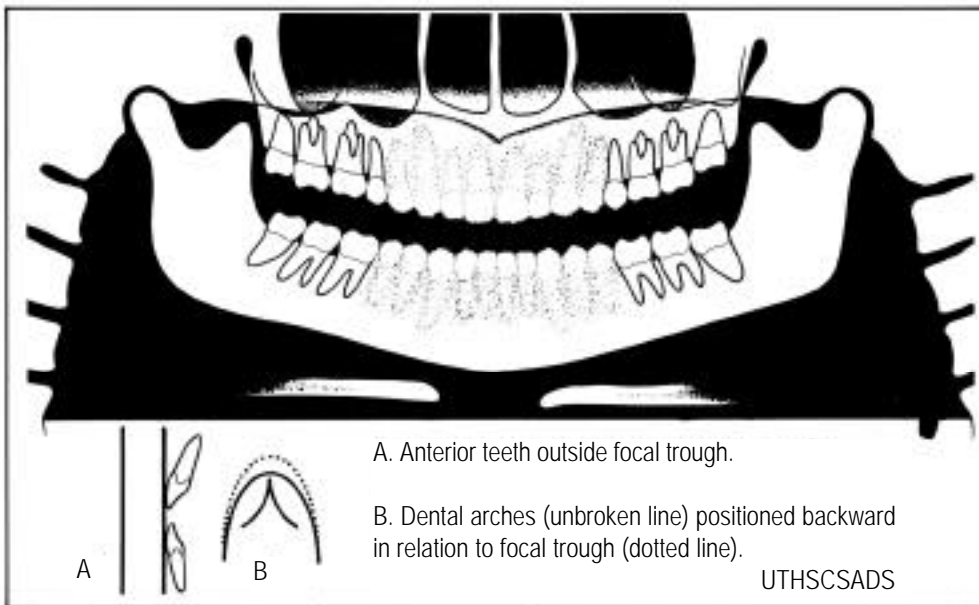
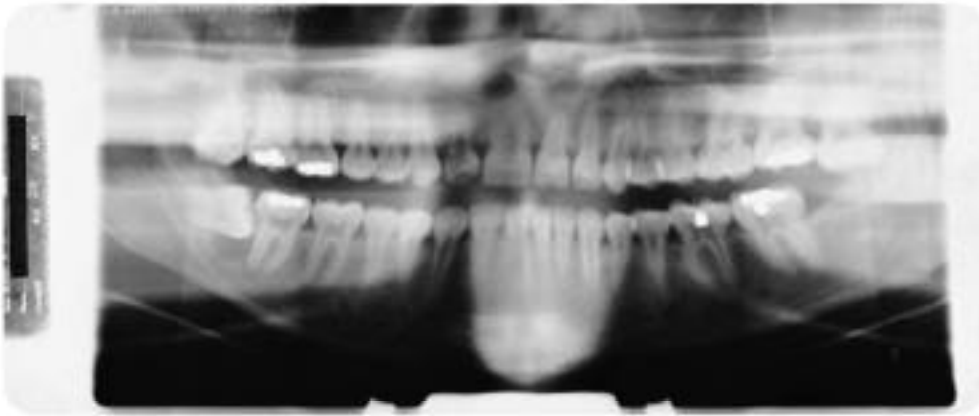
**PROBLEM:** Anterior teeth in both arches are out-of-focus, they are blurred and **narrow** in appearance; spine is superimposed on ramus areas; pre-molars are severely overlapped.

**CAUSE:** Patient positioned too far forward in relation to the image layer.

**HOW TO CORRECT:** Check to be sure the patient's teeth are correctly biting the bite block. The anterior incisors must be in the groove indicated on the block. Reposition the patient in chin rest according to manufacturers' recommendation.

**HINTS:** This problem usually occurs when the anterior teeth are missing. In order to maintain the slight distance that the anterior teeth would have had in relation to the ridge, the patient's ridge should be placed slightly **behind** the groove (toward the x-ray source) in the bite block. A roll of cotton or gauze could be used to raise the ridge to a more normal orientation.

If this problem persists, the chin rest or bite block may be incorrectly positioned. If the chin rest is not adjustable, correction may require the assistance of the manufacturer.



**Illustration No. 9:** Patient is positioned too far back. Patient is also slightly twisted.  
 (Film courtesy of Dr. Pirkka Nummikoski, UTHSCSADS)

**PROBLEM:**

Anterior teeth of both arches are out-of-focus; they are blurred and **wide** in appearance; excessive ghosting of mandible spine.

**CAUSE:**

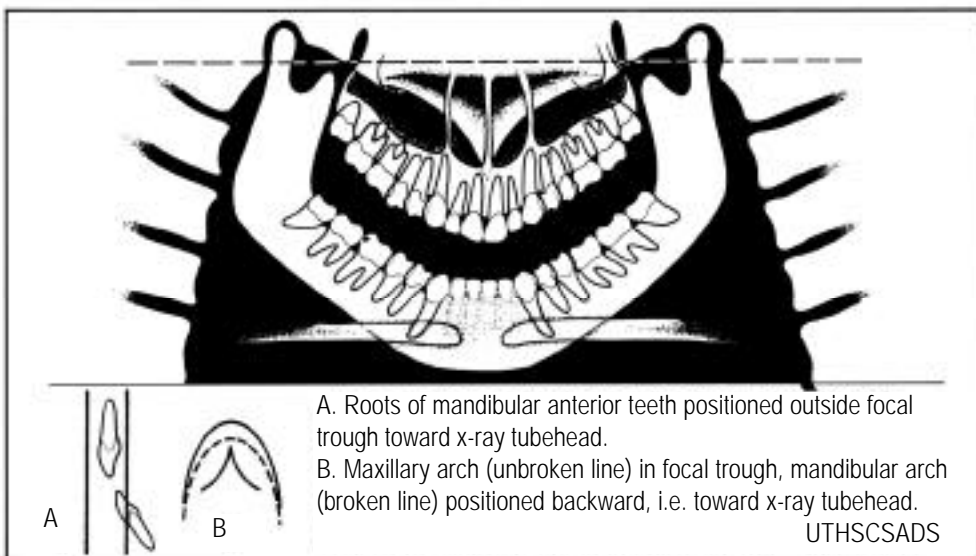
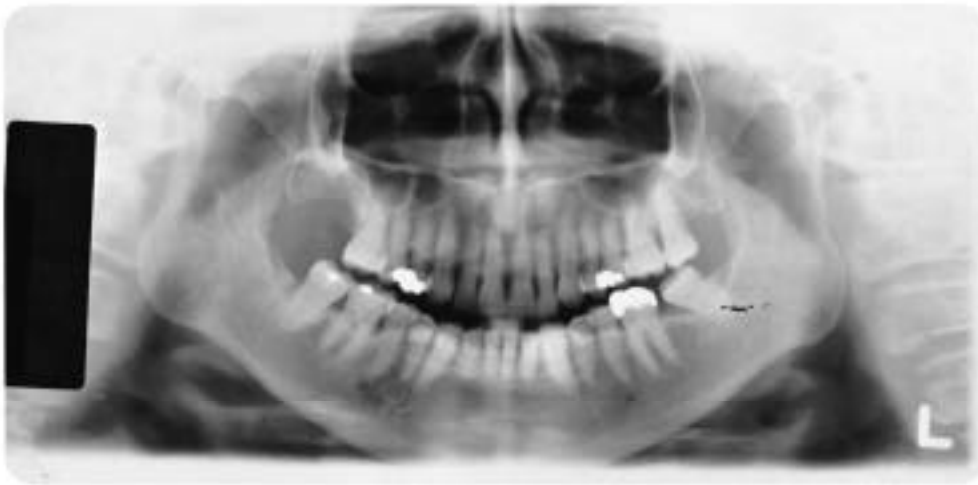Wide, blurred anterior teeth are caused by the patient being positioned too far back in relation to the image layer. This also may increase ghosting of the mandible and spine.

**HOW TO CORRECT:**

Check the placement of the patient's chin in the chin rest and position of the incisor teeth in the bite block groove.

**HINTS:**

The anterior portion of the image layer is very narrow (See Illustration No. 2, page 4). As a result, any flaring of dentition may not allow crowns and apices of both arches to fit in the image layer at the same time. If the patient has anterior teeth which are very flared-out, correct positioning of incisors in the groove will result in the above error. For these patients, you must purposely move him/her further forward in order to move the apices into the image layer. (Crowns can be examined clinically).



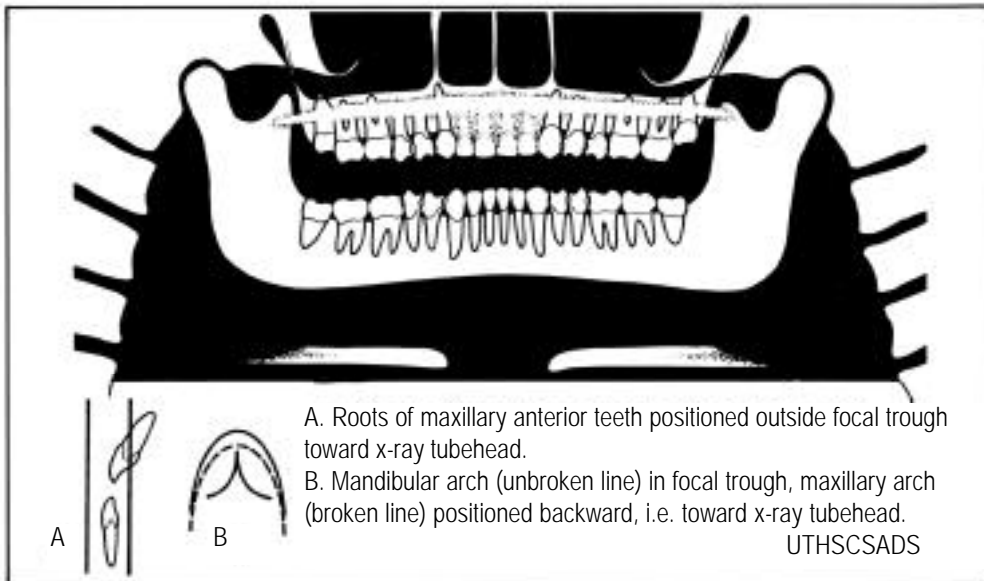
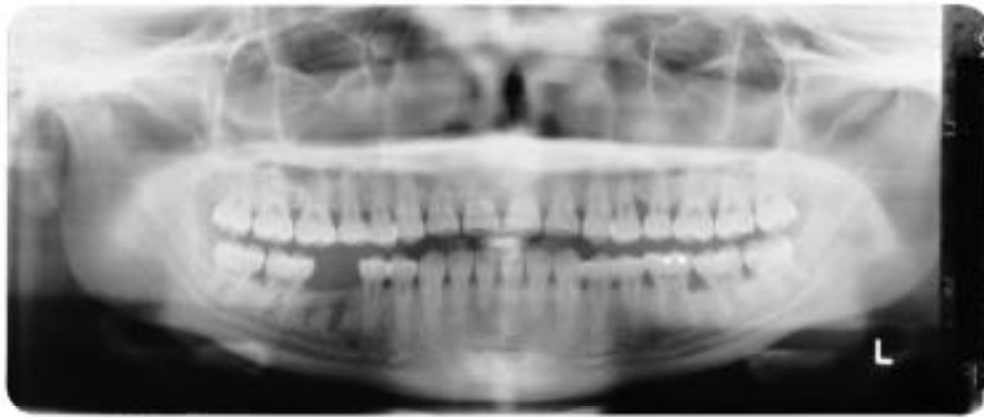**Illustration No. 10:** Patient's head is tilted downward. The dark masks over the left mandibular molar are due to static (see page 21)

**PROBLEM:** Apices of lower incisors are out-of-focus and blurred; shadow of hyoid bone is superimposed on anterior mandible; condyles may be cut off at the top of radiograph; pre-molars are severely overlapped.

**CAUSES:** Patient's head is tilted downward; chin is positioned back while forehead is positioned forward.

**HOW TO CORRECT:** Follow the directions by the equipment manufacturer on how to position anatomical points on the face with the reference line on the unit. Illustration No. 3, on page 5, shows common anatomical planes/lines that correspond with the reference lines on the panoramic units.

**HINTS:** Each panoramic equipment manufacturer has different instructions on how to align anatomical structures with specific lines on the machines. If the reference lines are missing or not seen, alignment would be closer to being correct if the occlusal plane was positioned approximately minus 5 degrees from parallel to the floor. It is better to err with the chin "too far down" than "too far up."



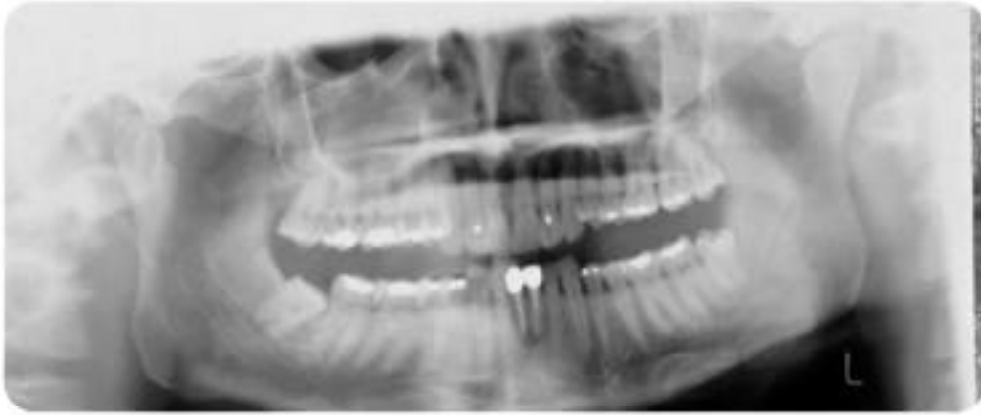**Illustration No. 11:** Patient's head is tilted upward.

**PROBLEM:** Upper incisors are out-of-focus; hard palate is superimposed over apices of maxillary teeth; both condyles may be off the edges of the film.

**CAUSES:** Patient's head is tilted upward; chin may be too far forward, while forehead is tilted toward the back.

**HOW TO CORRECT:** Follow the directions provided by your equipment manufacturer on how to position anatomical points on the face with the reference line on the unit. Illustration No. 3, on page 5, shows common anatomical planes that correspond with the reference lines on the panoramic units.

**HINTS:** This error can be intentionally created if you wish to more clearly see the lower anterior incisors and surrounding bone, especially with panoramic equipment that allows collimation so that a limited segment of the jaw can be imaged.



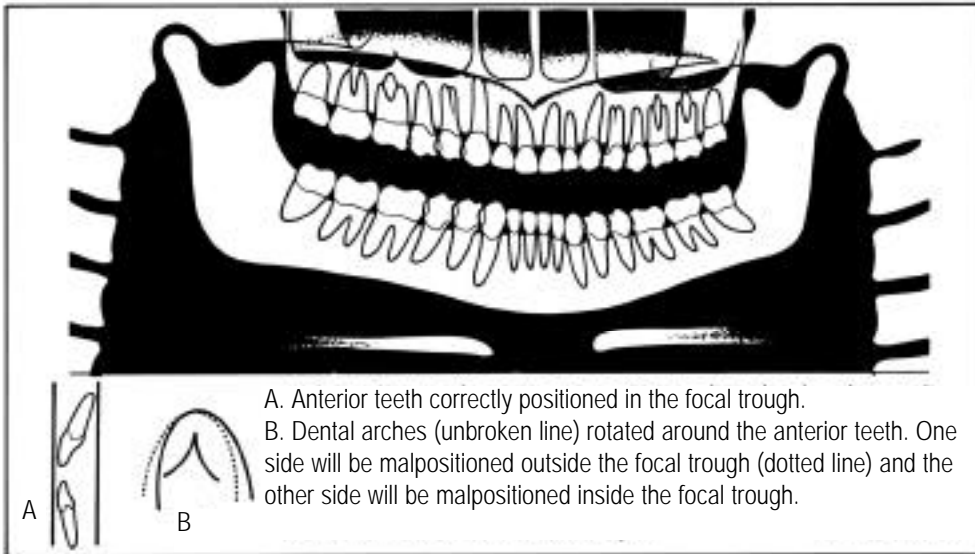
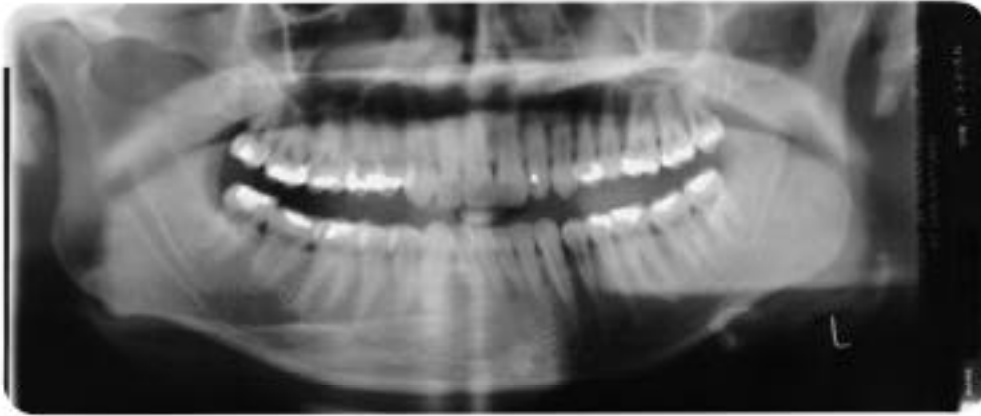
**Illustration No. 12:** Patient's head appears tilted.

**PROBLEM:** One condyle is definitely larger than the opposing one; the neck also is longer on the large side; image appears to be tilted; one angle of the mandible is higher than the other.

**CAUSES:** Patient's head is tilted to one side; anatomical variations; film is crooked in cassette--5 in. (12.7 cm) film in a 6 in. (15 cm) holder.

**HOW TO CORRECT:** First determine if the problem is anatomical/pathological rather than an error. If it is an error, and the panoramic unit is equipped with a positioning light, adjust the patient's head until the vertical positioning light aligns with the mid-sagittal line of the patient. If there is no positioning light, align the mid-sagittal plane visually so that it is perpendicular to the floor.

**HINTS:** There may be an anatomical/pathological reason for a difference in condyle size between right and left. If the occlusal plane is parallel to the bottom edge of the film, the difference is probably anatomical/pathological. On machines with mirrors, you can tape a vertical line on the mirror that the patient can use as a reference point.



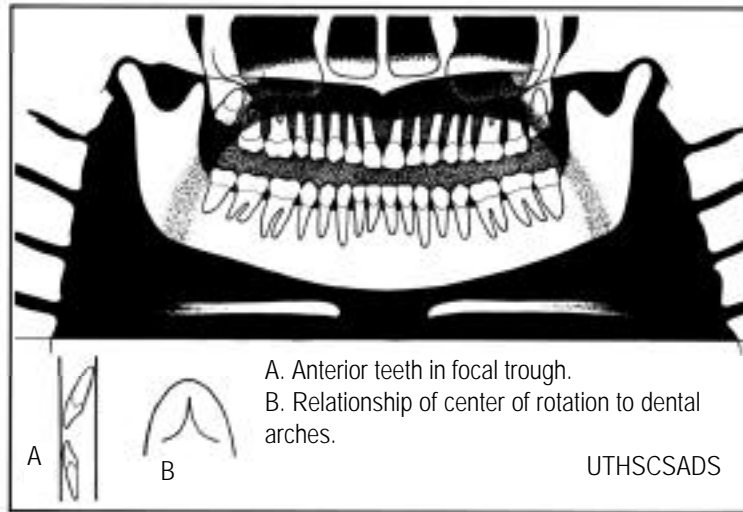
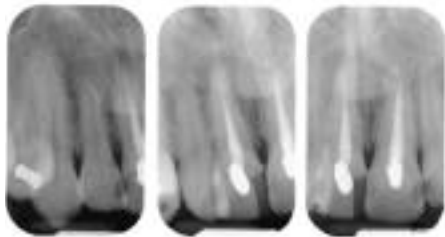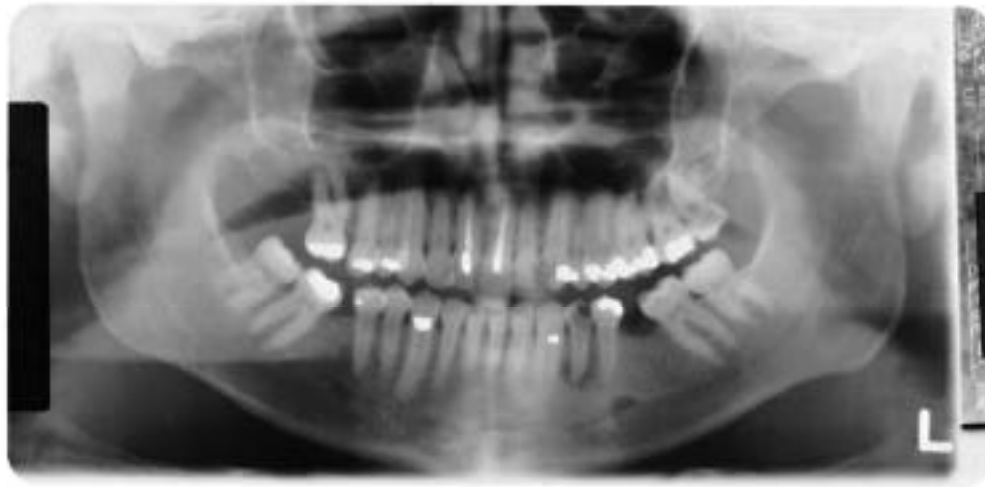**Illustration No. 13:** Patient's head is twisted.

**PROBLEM:** The teeth on one side of the midline appear wide and have severe overlapping of contacts, whereas teeth on the opposite side appear very narrow. Ramus on one side is much wider than the other. Condyles differ in size.

**CAUSES:** Patient is twisted to one side (right or left) causing the mandible to fall outside the image layer. One side is in front of the image layer while the other side is behind the image layer; anatomic variation asymmetry.

**HOW TO CORRECT:** Problem usually lies with the alignment of the mid-sagittal plane. The tip of the nose and the center of the chin must fall on the reference line. (See Illustration No. 3, page 5, for typical reference lines.)

**HINTS:** If no reference line exists, one should be added to the equipment. A visual exam of the patient will identify the asymmetric patient. If there is an anatomical variation or a pathological difference in the size of the ramus, the teeth will not display a difference in size between right and left.



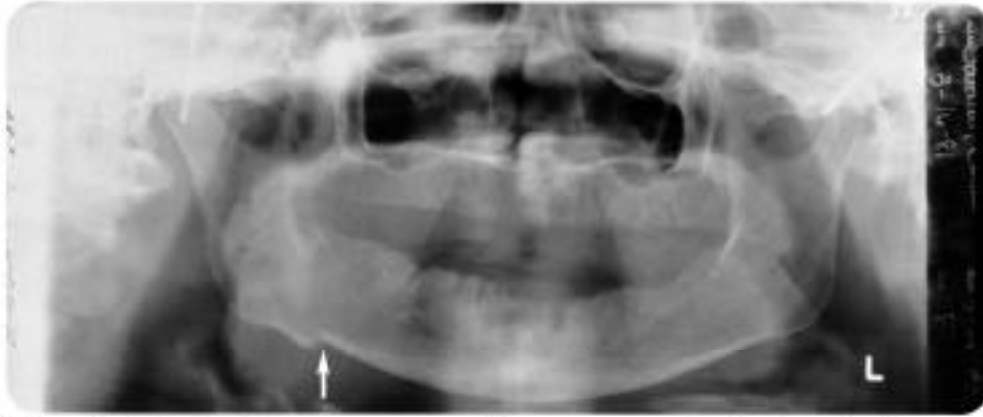
**Illustration No. 14:** Patient's tongue was not held closely to the roof of the mouth during the exposure. As a result, a radiolucency associated with the upper central incisor was not discernible in the panoramic view. The radiolucency can be seen in the intraoral views.

**PROBLEM:** Dark shadow in the maxilla below the palate; maxillary apices are obscured.

**CAUSE:** Patient's tongue was not fully placed against the roof of the mouth.

**HOW TO CORRECT:** Ask the patient to place tongue fully against the roof of the mouth and hold it there during the exposure. If only a portion of the film shows a dark area, patient may have lowered the tongue during exposure.

**HINTS:** To help patients understand about placing the tongue, ask the patient to swallow and note how the tongue feels against the roof of the mouth. Then, ask the patient to hold that position for the duration of the exposure.



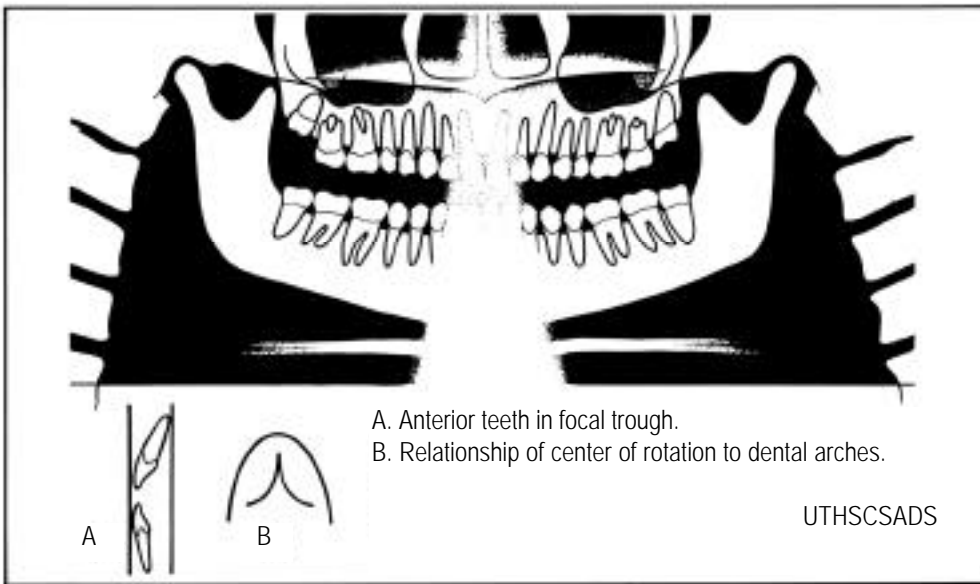
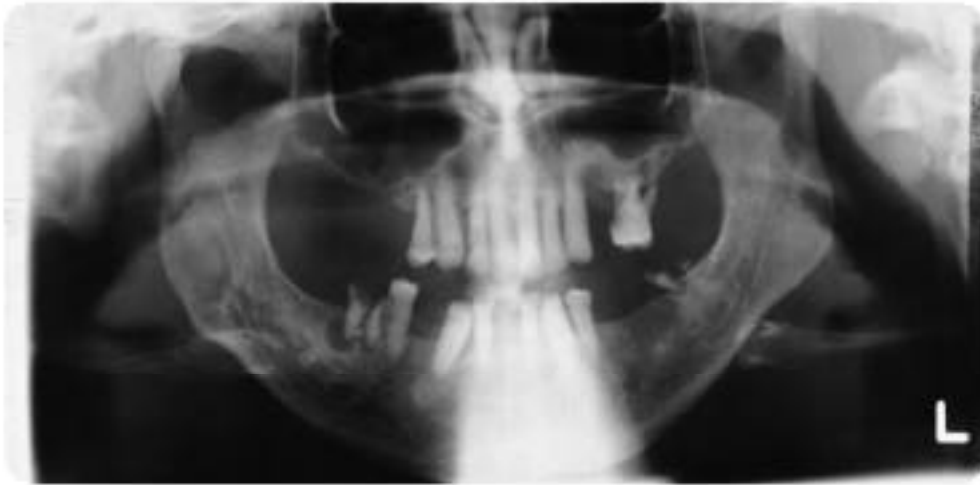**Illustration No. 15:** Patient movement during exposure. Note the irregularity on the inferior border of the right mandible (indicated by an arrow).

**PROBLEM:** Portion of the image is blurred; lacks sharpness.

**CAUSE:** Blurred images on radiographs are the result of motion during exposure. Because only a small increment of panoramic film is being exposed at one time, patient movement results in only one portion of the image being blurred.

**HOW TO CORRECT:** Remind the patient to remain perfectly still during the exposure. An anxious patient who is unfamiliar with the equipment may react to the movement of the machine.

**HINTS:** Take time to explain to the patient about the equipment movement prior to taking a panoramic x-ray. It will avoid a lot of problems. Determine the length of the exposure on your equipment and tell the patient the approximate time it will take to complete the exposure. By providing this information, the patient will have a better idea about how long he/she will have to remain relatively motionless. If the patient has a very wide head or protruding ears, these structures may touch the receptor portion of the machine during rotation. The patient may, inadvertently, move his/her head in the direction of the machine's movement.



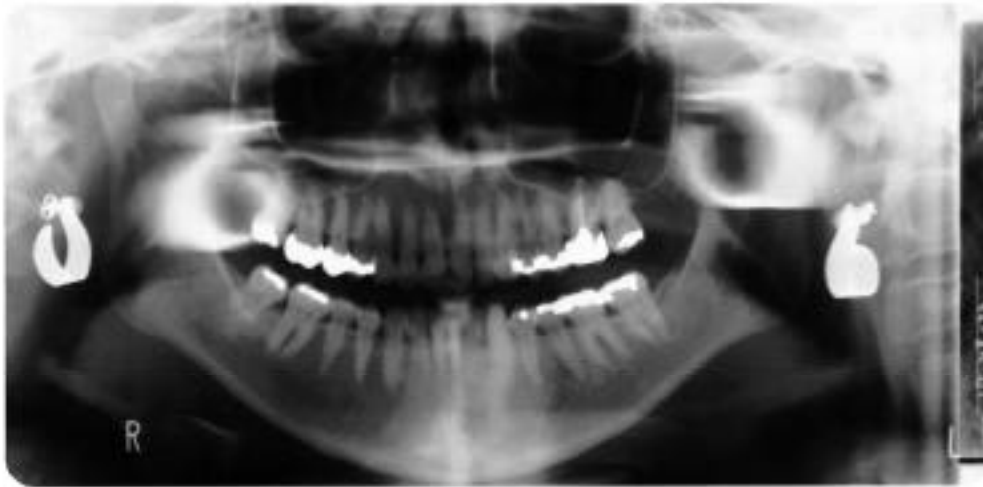
**Illustration No. 16:** Ghost image of the spine due to the patient being slumped.

**PROBLEM:** Pyramid-shaped opacity appears in the middle of the panoramic image.

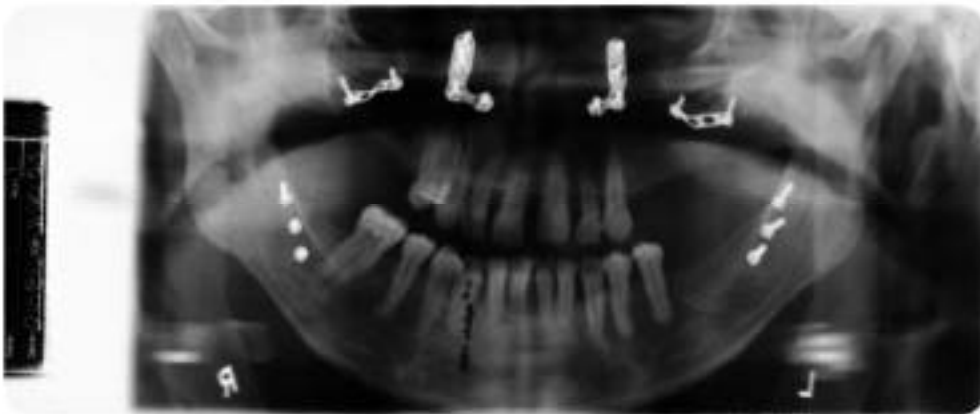
**CAUSES:** Patient was slumped; spinal column was not erect, causing a ghost image of the spine to be superimposed in the center of the film.

**HOW TO CORRECT:** Keep the spine erect. Don't allow patients to "reach" their chin to the chin rest. Ask them to "drop" (lower) their shoulders.

**HINTS:** Patients with short, thick necks or those with arthritis, may not be positioned in such a way as to eliminate this artifact; however, the posterior teeth and related structures will not be affected.



**Illustration No. 17A:** Ghost images due to the earrings.



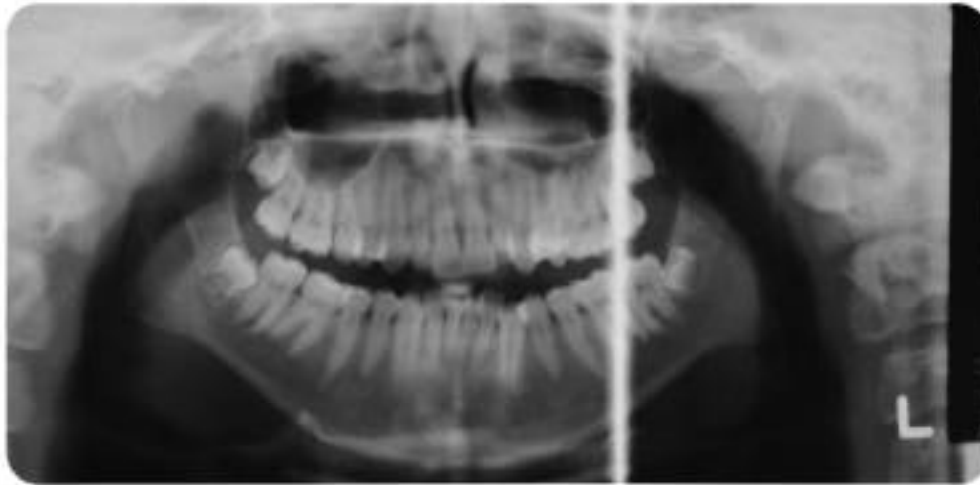
**Illustration No. 17B:** The numerous pieces of metal seen in this radiograph are located between the center of rotation and the film throughout the exposure; therefore, they are not susceptible to ghosting. Note ghosting of the "R" and "L." (The dark marks through the right canine and mandible are due to static; see page 21.)

**PROBLEM:** Ghost image appears on film (white artifact).

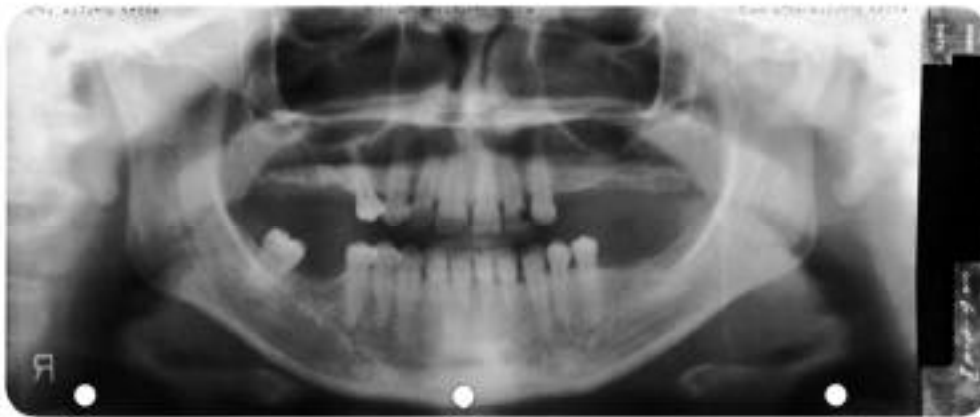**CAUSE:** "Reflected" image of a structure that was situated between the x-ray source and the center of rotation.

**HOW TO CORRECT:** When possible, common objects that are susceptible to ghosting should be removed. Examples are: earrings, neck chains, napkin chains, hair pins, hearing aids, ornamental hair pieces, etc.

**HINTS:** During one-half of the rotation, certain structures or objects may be in front of the center of rotation, in or near the image layer. In this case, the "real" image is recorded. These same structures/objects will be located behind the center of rotation during the second half of the rotation. In this case, the structures/objects will appear as "ghosts" superimposed on the opposite side from the "real" image. The ghost image is enlarged and appears to be at a slightly higher level than the real image. Both anatomical structures (e.g., cervical spine, hyoid bone) and common objects (e.g., earrings, neck chains) are capable of becoming ghost images.



**Illustration No. 18A:** The solid opaque line was caused by releasing the exposure button momentarily during exposure.



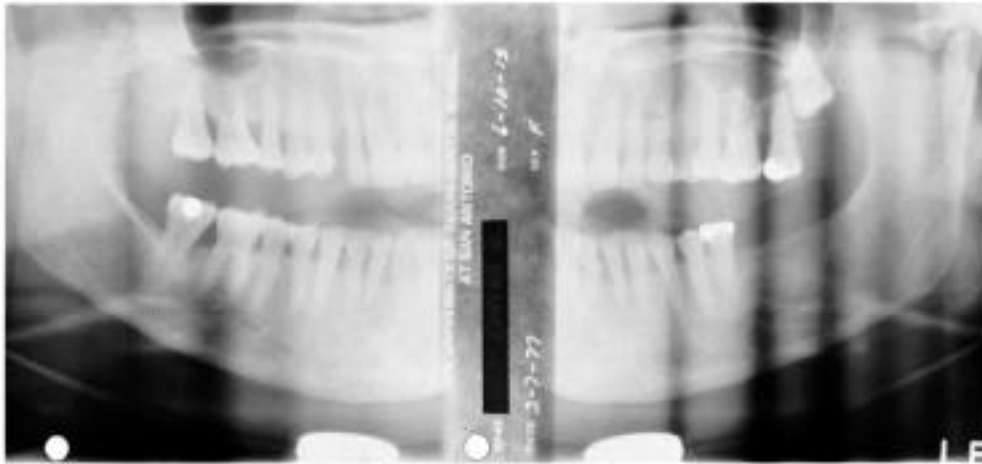
**Illustration No. 18B:** The white irregular line was created by a crack in the intensifying screen.

**PROBLEM:** Random white (minus density) artifacts seen on the film.

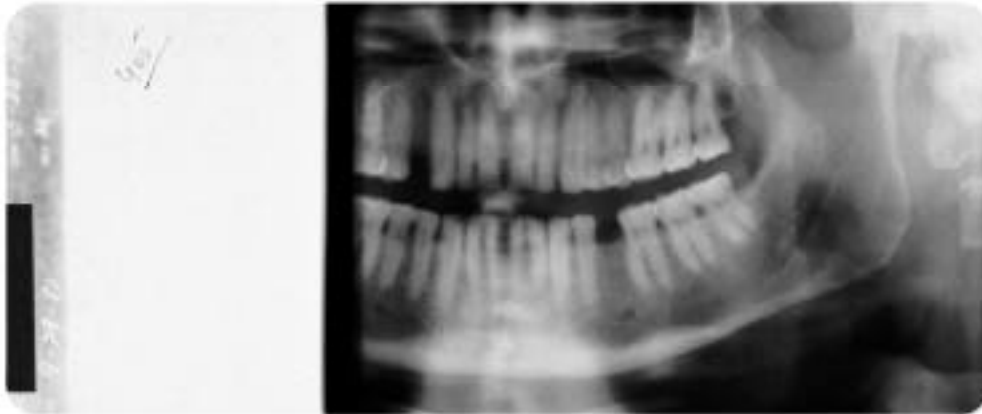
**CAUSES:** Lint or small pieces of debris between film and screens; intensifying screen scratched or gouged; contact with fixer dust or solution; exposure error.

**HOW TO CORRECT:** Clean intensifying screens to remove dirt or lint; check them for scratches or breaks in the surface. Keep surfaces in the darkroom area clean.

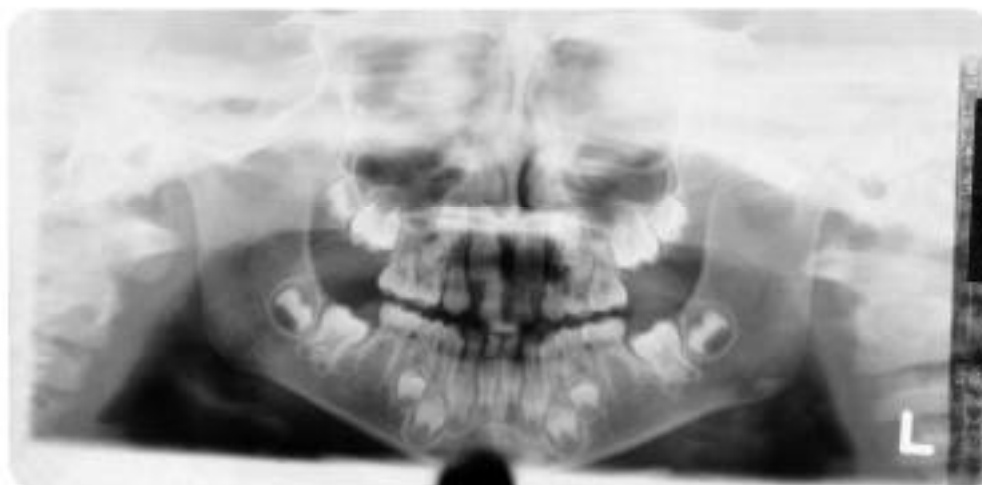**HINTS:** The phosphor layer of the intensifying screens absorbs the x-rays and then converts them to light in the form of a fluorescent glow which exposes the film. If some of the screen surface is removed accidentally through scratches or blocked by foreign material in the cassette, the "glow" from that area will be less, creating an unexposed area and, therefore, a white (minus density) artifact on the film. When drops of chemicals evaporate, a chemical dust is created. If film comes in contact with fixer dust or solution, the emulsion can clear before processing.



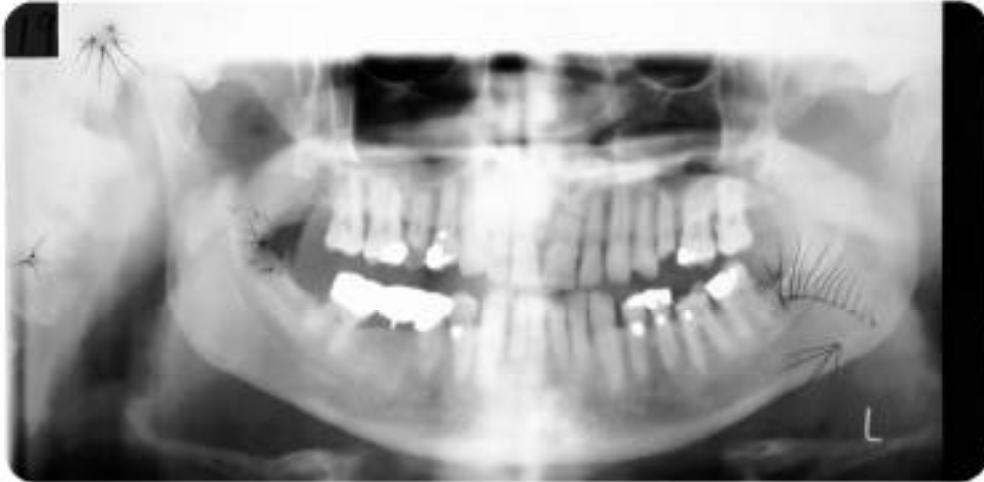**Illustration No. 19A:** The black lines on this radiograph are the result of irregular movement of the machine. The cause may be a worn part.



**Illustration No. 19B:** The dense, black edge seen at one end of the radiographic image was caused by continuous exposure of the film when rotation of the unit had stopped. The rotating unit stopped when it came in contact with the patient's shoulder.



**Illustration No. 19C:** The dark area on the lower edge of the film was due to a light leak from an open seam in the flexible cassette.



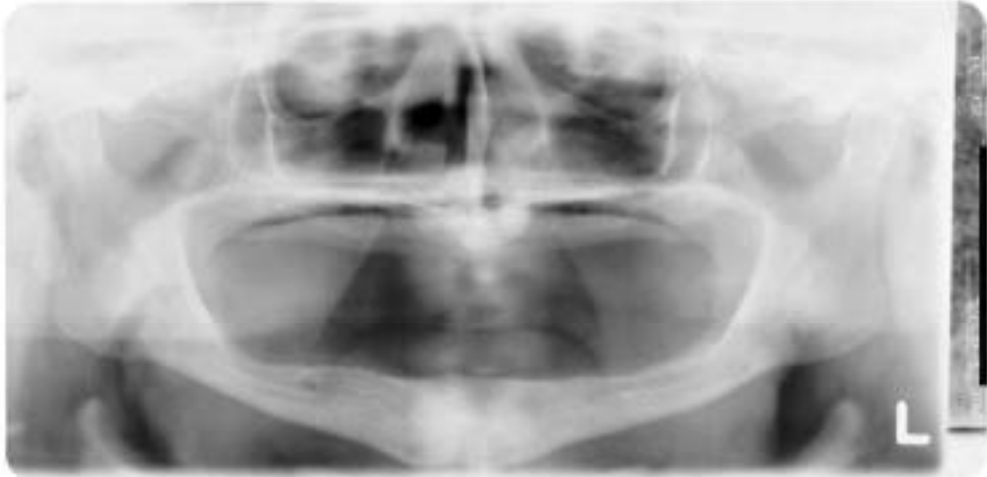
**Illustration No. 19D:** Classic “tree-like” marks from static electricity.  
 (Courtesy, Department of Dental Diagnostic Science, UTHSC Dental School, San Antonio, Texas).

**PROBLEM:** Dark (plus density) artifacts seen on the film.  
 Black vertical lines or “tree-like” marks seen on the film.

**CAUSES:** Crimped or creased film; localized overexposure; processing chemicals; and static electricity.

**HOW TO CORRECT:** Handle film with caution. Rough handling or creasing the film will cause a black artifact to appear on the film. Overexposures may be due to a mechanical problem or through a change in electrical power. Static is normally caused by low humidity or static producing objects. Increase in humidity in the room where the film is stored: 50-75% is recommended. Place rubber mats on the floor where film is unboxed and placed in the cassette. Carefully remove exposed film from the cassettes. Antistatic solutions may be applied with gauze sponges to carefully clean the screen. This reduces the possibility of static artifacts.

**HINTS:** The sensitivity of film increases at the site when creased, leaving a black mark sharply defined on the film. Patient’s shoulder may have impeded movement of film momentarily causing an overexposure of that portion of the film. Voltage coming into the machine may be uneven; film drum lock may become engaged, resulting in an overexposure of the affected area. If the film comes in contact with the chemicals in powder or solution form, the emulsion may be affected. Static electricity can cause localized overexposure; if held too near, the glow of a cigarette can also fog unprocessed film. Static electricity appears “tree-like” or as a smudge. (Also see Illustration Nos. 6, 10 and 17 on pages 8, 11 and 18 respectively). Protective gloves are one source of static electricity. In areas where humidity cannot be controlled, avoid rapidly pulling the film out of the package. Hold the film only at the corners. Turning the white lights on in a darkroom before the film has completely entered an automatic processor will result in complete blackening of the trailing edge of the film.



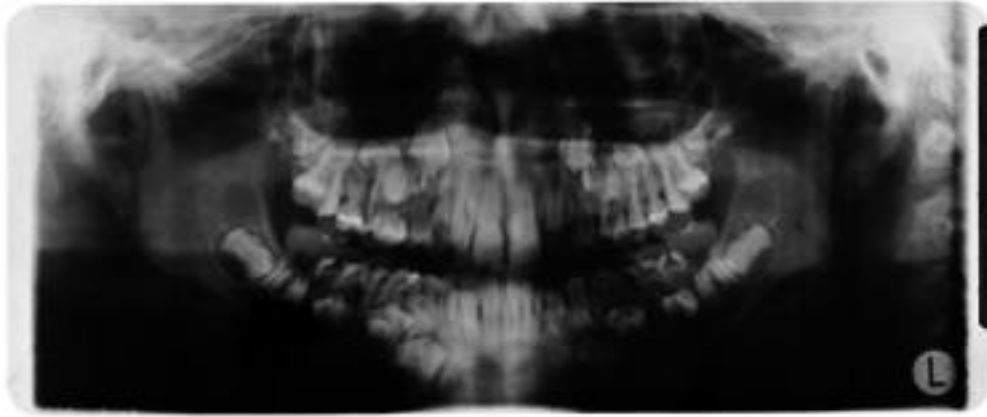
**Illustration No. 20:** Image too light due to underprocessing or underexposure.

**PROBLEM:** Image is too light (thin); washed out; no detail seen; image is very faint or not seen at all.

**CAUSES:** X-ray beam energy level is too low and not producing enough radiation to properly expose film; processing time in developer is too brief; chemicals are too old or exhausted; processing temperature is too cold; screens are reversed.

**HOW TO CORRECT:** Compare the manufacturer's recommended settings with your kVp setting. Check the temperature of the processing solutions, particularly the developer. A temperature that is too cold will slow down the action of the developer. In an automatic processing system, check the speed of the film transport system. A fast speed will reduce the processing time in the developer, producing light film. Slowing down the rate or raising the developer temperature are options, but must be done according to manufacturer's recommendations. Reversing screens can result in a **very** faint image or no image at all. To be sure that the screens are loaded correctly in a flexible cassette, the words "KODAK LANEX Regular" imprinted on the edge **must** face the film on each side.

**HINTS:** Exposure settings are usually based on average-sized patients. Whenever the image is very light or thin, first consider the size and body structure of the patient; then check the exposure setting. (Refer to Illustration No. 5, on page 7)



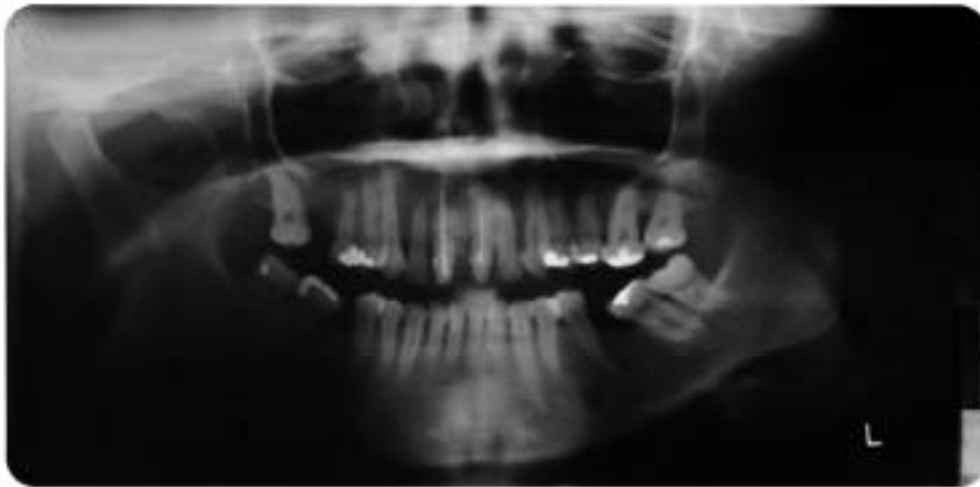
**Illustration No. 21:** Image too dark due to a double exposure.

**PROBLEM:** Image is dark (dense); structures not seen.

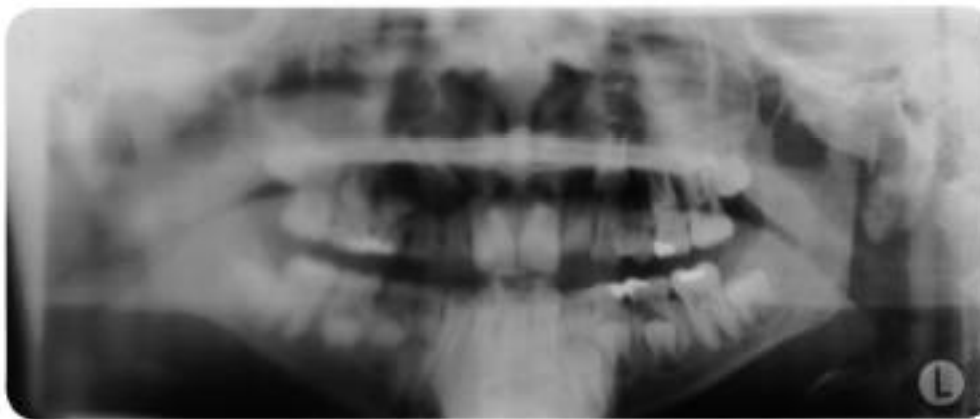
**CAUSES:** X-ray beam energy level is producing too much radiation and overexposing the film; processing time in developer is too long; processing temperatures are too high; double exposure of film.

**HOW TO CORRECT:** Compare manufacturer's recommended settings against your kVp setting. Check the temperature of the processing solutions, particularly the developer. A warmer temperature will increase the action of the developer. In automatic processing systems, check the speed of the film transport system. A slow rate will increase processing time. This may result in a darker film. To avoid double exposures, establish a protocol which will prevent cassettes from being reused.

**HINTS:** Exposure settings are usually based on average-sized patients. Whenever the image is very dark or dense, first consider the size and body structure of the patient; then check the exposure setting. (Refer to Illustration No. 5, on page 7)



**Illustration No. 22A:** Film is fogged. Note the gray coloring of the restorations in the overexposed area on the lower left segment of the film.



**Illustration No. 22B:** This film appears to be fogged on patient's right side, however, this is blurring due to improper film-screen contact which can occur if the cassette is not properly locked or mounted. Note the overexposure from light leak on lower left corner of the film.

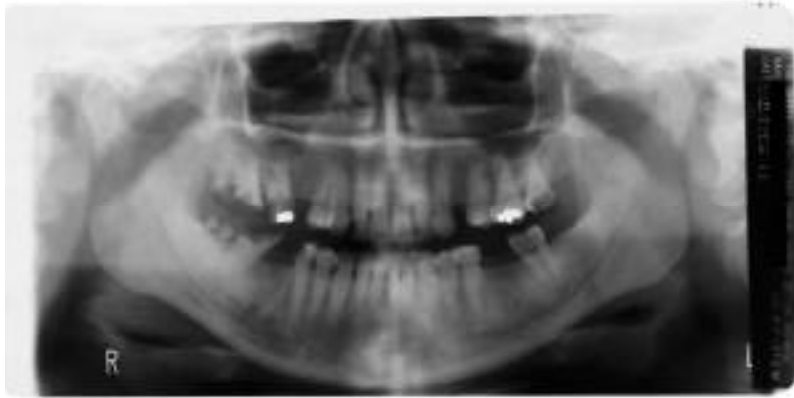**PROBLEM:** Film is fogged; overall darkening of film.

**CAUSES:** Old film or improper storage conditions; secondary exposure of film to x-radiation; exposure to white light; exposure to wrong color safelight; safelight lamp wattage too high; safelight too close to work area; chemical fog.

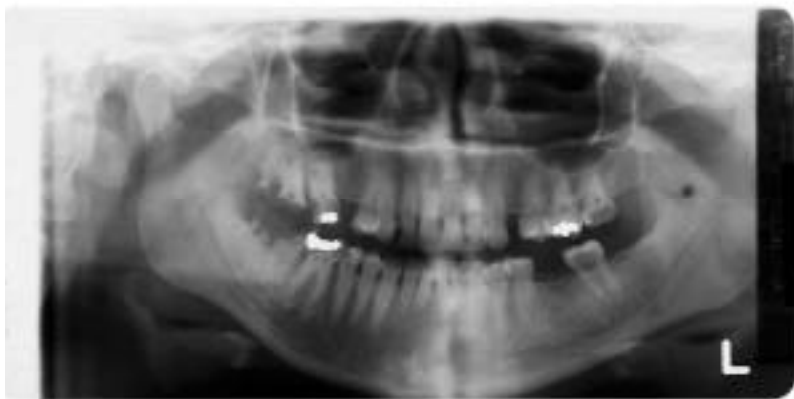**HOW TO CORRECT:** Check the following: date of expiration on film packets; storage room temperature; light leaks in the darkroom; possible other light sources (cigarettes, coffee pot lights, etc); darkroom safelight filter (KODAK GBX-2 Safelight Filter is suggested); wattage size of safelight bulb; distance of the safelight from working surface. (Recommendations: 15W lamp at 4ft [1.2m] using a standard 110V U.S.A. system or 25W at 4ft [1.2m] using a 220-240 V European system). The age of the developer and fixer solutions should be checked, as well as the chemicals used to replenish.

**HINTS:** Special care is needed to protect film. For example: prolonged exposure of film to temperatures above 70 degrees F (21 degrees C) will fog film; humidity, chemical fumes and x-radiation are all hazardous to stored film. Periodically process one sheet of unexposed film to check on storage conditions. Keep unused film in sealed boxes. Purchase film in quantities that can be used within 1-2 months. Use lead-lined box to store film. The GBX or GBX-2 Safelight Filters can be used with extraoral dental film. The ML-2 or OAFilters are not safe for use with extraoral dental film. To differentiate between overexposed film and fogged film, look at restorations: in an overexposed film they will appear white; in a fogged film they will appear gray.

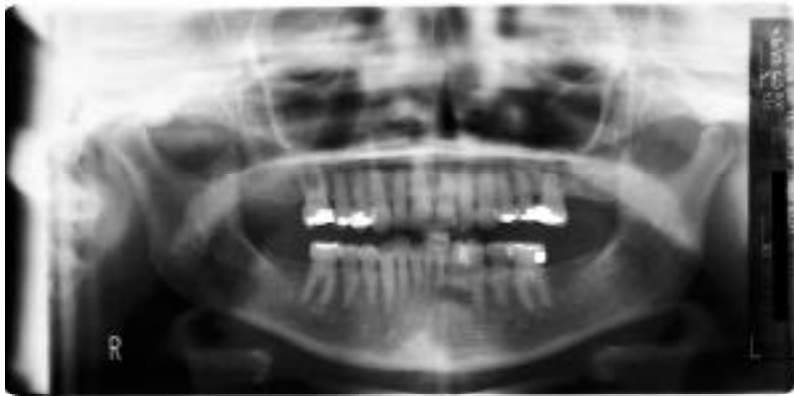
ANSWER PAGE:



**Illustration No. 23:** This is a panoramic view taken five months later of the same patient shown in Illustration No. 6 below. Compare the dimensions of this properly exposed radiograph with the earlier radiograph.



**Illustration No. 6:** The errors seen in this radiograph are: 1.) Head is tilted-right and left mandible angles are not located at the same distance from the lower edge of the film. 2.) Head is twisted-left ramus and teeth are wider than those on the right side. 3.) Cassette was not started in the proper position resulting in an image on the portion of the film normally left unexposed for the label. In this case, the label obscures a portion of the image. 4.) Radiolucency on left ramus is a result of static electricity whereas a similar radiolucency on the upper-right lateral is missing tooth structure.



**Illustration No. 7:** The errors seen in this radiograph are slight, but together they result in a film of poor diagnostic quality. 1.) Chin up. 2.) Head twisted. 3.) Tongue away from palate.

EASTMAN KODAK COMPANY  
Dental Business  
Health Imaging Division  
343 State Street  
Rochester, NY 14650-1123  
(1-800-933-8031)

KODAK CANADAINC.  
Health Imaging Division  
3500 Eglinton Ave. W.  
Toronto, Ontario M6M 1V3  
CANADA  
(1-800-4656325)

<http://www.kodak.com/go/dental>

Kodak and Lanex are trademarks.

*Bringing more to the picture*

